

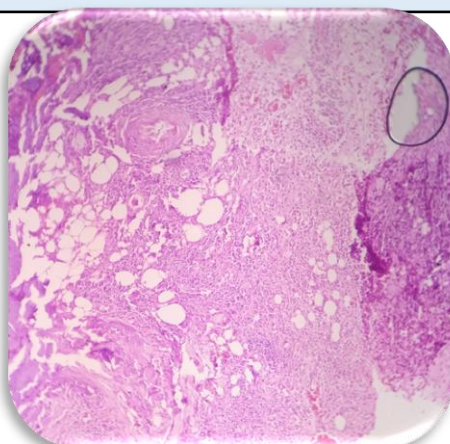
# INFECTIVE CYSTIC LESION.

<b>Patient Name</b>	Mr. ASHOK KUMAR	<b>Client Name</b>	Samvedna Hospital,	<b>Specimen Received</b>	09/07/2018
<b>Age/Sex</b>	43/M		Narnaul	<b>Specimen Type</b>	Tissue
<b>Patient ID</b>	011807090330	<b>Client Code</b>	MolQ1794CW	<b>Collection Date</b>	09/07/2018
<b>Specimen ID</b>	MOLQ/B-683-18	<b>Ref. Doctor</b>	Dr. MANOJ	<b>Report Date</b>	13/07/2018

## SURGICAL PATHOLOGY REPORT POST AURICULAR SWELLING.

### DIAGNOSIS

**INFECTIVE CYSTIC LESION.**



### SPECIMEN

Post auricular swelling.

### GROSS

Received 1.0 x 1.0 cm greyish white tissue piece.

### Microscopy

1. Section examined shows fibro collagenous tissue, large number of blood vessels, inflammatory cells, few multi nucleated giant cells.
2. No granuloma seen.
3. No malignant cells seen.

**Note :** All biopsy specimen will be stored for 15 (fifteen)days, block and slides for 5(five) years only from the time of receipt at the laboratory. No request ,for any of the above ,will be entertained after the due date.

### Reference

- i) Rosai and Ackerman's Surgical Pathology.
- ii) Modern Surgical Pathology.

A handwritten signature in black ink, appearing to read 'Gulshan', written over a light blue rectangular background.

**Gulshan Yadav, MD**  
Consultant Pathologist