

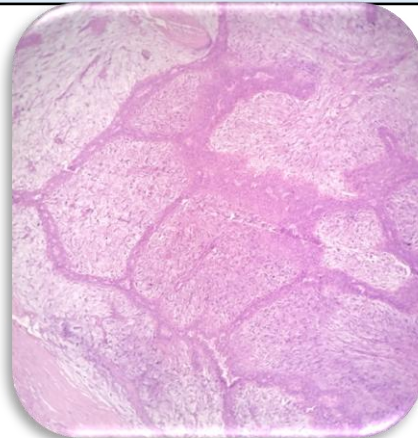
<b>Patient Name</b>	Mrs. Saroj	<b>Client Name</b>	Civil Hospital P, Gurgaon.	<b>Specimen Received</b>	04/07/2018
<b>Age/Sex</b>	40/F	<b>Client Code</b>	MolQ1781P	<b>Specimen Type</b>	Tissue
<b>Patient ID</b>	011807040106	<b>Ref. Doctor</b>	BALWINDER SINGH JI	<b>Collection Date</b>	04/07/2018
<b>Specimen ID</b>	MOLQ/B-646-18			<b>Report Date</b>	09/07/2018

## SURGICAL PATHOLOGY REPORT

### RIGHT BREAST.

#### DIAGNOSIS

**BENIGN BREAST LESION.**



#### SPECIMEN

Right Breast.

#### GROSS

Received 3.0 x 2.1 cm greyish white tissue piece.


#### Microscopy

1. Section examined shows large number of ducts lined by cuboidal to columnar lining epithelium with small round to oval nucleus surrounded by fibro collagenous and inflammatory cells.

**Note :** All biopsy specimen will be stored for 15 (fifteen)days, block and slides for 5(five) years only from the time of receipt at the laboratory. No request ,for any of the above ,will be entertained after the due date.

#### Reference

- i) Rosai and Ackerman's Surgical Pathology.
- ii) Modern Surgical Pathology.



**Gulshan Yadav, MD**  
**Consultant Pathologist**