

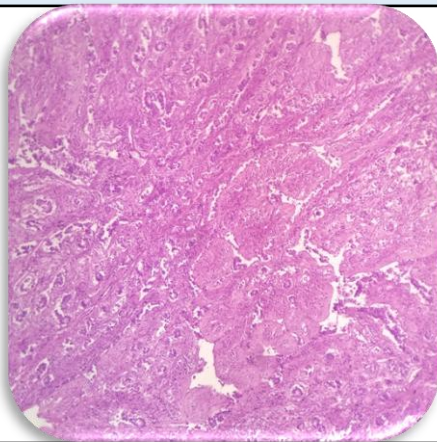
|                     |                |                    |                           |                          |            |
|---------------------|----------------|--------------------|---------------------------|--------------------------|------------|
| <b>Patient Name</b> | Miss. KHUSHBOO | <b>Client Name</b> | Patient Care Diagnostics, | <b>Specimen Received</b> | 02/07/2018 |
| <b>Age/Sex</b>      | 18/F           |                    | Faridabad                 | <b>Specimen Type</b>     | Tissue     |
| <b>Patient ID</b>   | 011807020144   | <b>Client Code</b> | MolQ1774CM                | <b>Collection Date</b>   | 02/07/2018 |
| <b>Specimen ID</b>  | MOLQ/B-629-18  | <b>Ref. Doctor</b> |                           | <b>Report Date</b>       | 06/07/2018 |

**SURGICAL PATHOLOGY REPORT**

**RIGHT BREAST.**

**DIAGNOSIS**

**BENIGN BREAST LESION.**



**SPECIMEN**

Right Breast.

**GROSS**

Received 4.0 x 3.8 cm greyish white tissue piece.

**Microscopy**

- Section examined shows large number of duct with cuboidal lining epithelium and small round nucleus surrounded by fibro collagenous tissue and blood vessels.

**Note :** All biopsy specimen will be stored for 15 (fifteen)days, block and slides for 5(five) years only from the time of receipt at the laboratory. No request ,for any of the above ,will be entertained after the due date.

**Reference**

- Rosai and Ackerman's Surgical Pathology.
- Modern Surgical Pathology.

**Gulshan Yadav, MD  
Consultant Pathologist**