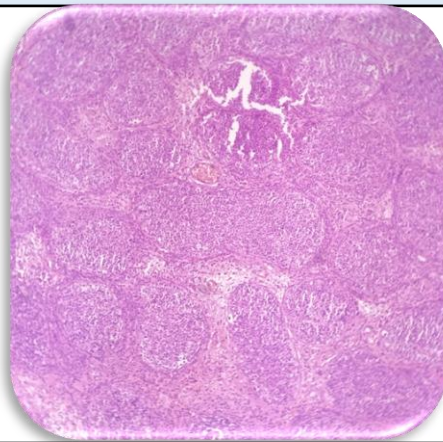


<b>Patient Name</b>	Mr. AJGAR	<b>Client Name</b>	Arban Hospital, Nuh .	<b>Specimen Received</b>	01/07/2018
<b>Age/Sex</b>	40/M	<b>Client Code</b>	MolQ1684P	<b>Specimen Type</b>	Tissue
<b>Patient ID</b>	011807010170	<b>Ref. Doctor</b>		<b>Collection Date</b>	01/07/2018
<b>Specimen ID</b>	MOLQ/B-626-18			<b>Report Date</b>	06/07/2018

**SURGICAL PATHOLOGY REPORT**  
**SWELLING IN LEFT SCROTUM.**

**DIAGNOSIS**

**ACUTE INFECTION.**



**SPECIMEN**

Swelling in left scrotum.

**GROSS**

Received 1.0 x 1.0 cm greyish white tissue piece.

**Microscopy**

1. Section examined shows seminiferous tubules filled with degenerated cell in large number if inflammatory cells (polymorphs and lymphocytes). Dermis shows fibrocollagenous tissue, calcified areas and few mononuclear cell infiltrate.
2. No granuloma seen.
3. No malignant cells seen.

**Note :** All biopsy specimen will be stored for 15 (fifteen) days, block and slides for 5 (five) years only from the time of receipt at the laboratory. No request ,for any of the above ,will be entertained after the due date.

**Reference**

- i) Rosai and Ackerman's Surgical Pathology.
- ii) Modern Surgical Pathology.

**Gulshan Yadav, MD**  
**Consultant Pathologist**