

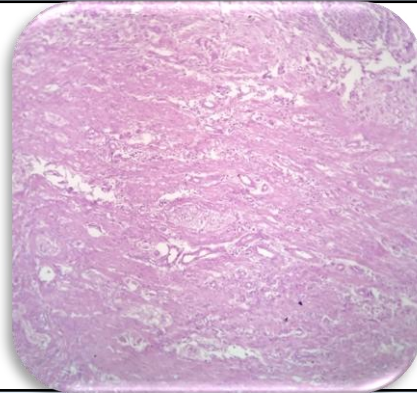
|                     |               |                    |                             |                          |            |
|---------------------|---------------|--------------------|-----------------------------|--------------------------|------------|
| <b>Patient Name</b> | Mrs. PUSHPA   | <b>Client Name</b> | Accurate Path (C),<br>Agra. | <b>Specimen Received</b> | 03/07/2018 |
| <b>Age/Sex</b>      | 26/F          | <b>Client Code</b> | MolQ1671CM                  | <b>Specimen Type</b>     | Tissue     |
| <b>Patient ID</b>   | 011807030005  | <b>Ref. Doctor</b> |                             | <b>Collection Date</b>   | 03/07/2018 |
| <b>Specimen ID</b>  | MOLQ/B-634/18 |                    |                             | <b>Report Date</b>       | 04/07/2018 |

## SURGICAL PATHOLOGY REPORT

### APPENDIX.

#### DIAGNOSIS

**ACUTE APPENDICITIS.**



#### SPECIMEN

Appendix.

#### GROSS

Received 3.0 X 0.8 cm long tissue piece.

#### Microscopy

1. Section examined shows lymphoid follicles with ulcerative mucosa.
2. Deeper tissue shows inflammatory cells.

**Note :** All biopsy specimen will be stored for 15 (fifteen) days, block and slides for 5 (five) years only from the time of receipt at the laboratory. No request, for any of the above, will be entertained after the due date.

#### Reference

- i) Rosai and Ackerman's Surgical Pathology.
- ii) Modern Surgical Pathology.

**Gulshan Yadav, MD**  
Consultant Pathologist