

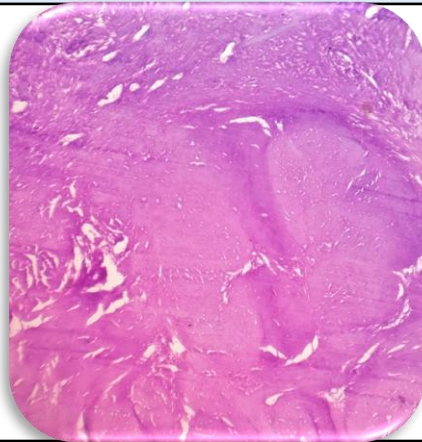
<b>Patient Name</b>	Mr. MANZOR AHMAD	<b>Client Name</b>	A-One Collection Centre,	<b>Specimen Received</b>	29/06/2018
<b>Age/Sex</b>	54/M		Jammu & Kashmir	<b>Specimen Type</b>	Tissue
<b>Patient ID</b>	041806290033	<b>Client Code</b>	MolQ1767P	<b>Collection Date</b>	29/06/2018
<b>Specimen ID</b>	MOLQ/B-621-18	<b>Ref. Doctor</b>		<b>Report Date</b>	02/07/2018

## SURGICAL PATHOLOGY REPORT

### RIGHT FOOT.

#### DIAGNOSIS

**KINDLY, CO-RELATE CLINICALLY.**



#### **SPECIMEN**

Right Foot.

#### **GROSS**

Received autolytic 1.0 x 2.0 cm yellowish tissue piece.

#### **Microscopy**

- Section examined shows autolytic changes in the tissue with loss of cellular details with fibrocollagenous tissue, blood vessels and inflammatory cell.

**Note :** All biopsy specimen will be stored for 15 (fifteen)days, block and slides for 5(five) years only from the time of receipt at the laboratory. No request ,for any of the above ,will be entertained after the due date.

#### **Reference**

- Rosai and Ackerman's Surgical Pathology.
- Modern Surgical Pathology.

**Gulshan Yadav, MD**  
**Consultant Pathologist**