

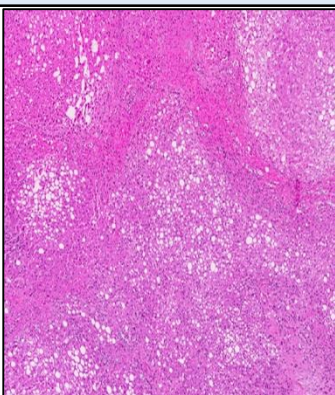
<b>Patient Name</b>	Mrs. PUSHPA	<b>Client Name</b>	Brijanand Path Lab	<b>Specimen Received</b>	22/06/2018
<b>Age/Sex</b>	45/F	<b>Client Code</b>	MolQ1133CM	<b>Specimen Type</b>	Tissue
<b>Patient ID</b>	011806220128	<b>Ref. Doctor</b>		<b>Collection Date</b>	22/06/2018
<b>Specimen ID</b>	MOLQ/B-598/18			<b>Report Date</b>	28/06/2018

## SURGICAL PATHOLOGY REPORT

### ENDOMETRIUM.

#### DIAGNOSIS

**PROLIFERATIVE PHASE.**



#### SPECIMEN

Endometrium.

#### GROSS

- 1) Received multiple greyish white tissue pieces.

#### Microscopy

- 1) Section examined shows small endometrial glands with cuboidal lining epithelium with round to oval nucleus.
- 2) Stroma shows mononuclear inflammatory cell.
- 3) No granuloma and no malignant cell seen.

**Note :** All biopsy specimen will be stored for 15 (fifteen)days, block and slides for 5(five) years only from the time of receipt at the laboratory. No request ,for any of the above ,will be entertained after the due date.

#### Reference

- i) Rosai and Ackerman's Surgical Pathology.
- ii) Modern Surgical Pathology.

**Dr. Gulshan Yadav, MD**  
Consultant Pathologist