

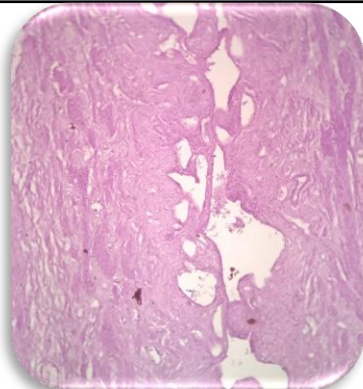
| | | | | | |
|---------------------|-----------------|--------------------|---------------------------------|--------------------------|------------|
| Patient Name | Mr. BHEEM SINGH | Client Name | Path Star Diagnostic, Delhi. | Specimen Received | 18/06/2018 |
| Age/Sex | 58/M | Client Code | MOLQ1098CM | Specimen Type | Tissue |
| Patient ID | 011806180282 | Ref. Doctor | | Collection Date | 18/06/2018 |
| Specimen ID | MOLQ/B-583/18 | | | Report Date | 21/06/2018 |

SURGICAL PATHOLOGY REPORT

GALL BLADDER.

DIAGNOSIS

CHRONIC CHOLECYSTITIS AND CHOLELITHIASIS.



SPECIMEN

Gall Bladder.

GROSS

Received 6.5 x 2.8 cms long gall bladder autolyzed. Cut section shows stones.

Microscopy

- Section examined shows autolyzed ulcerated lining epithelium with mononuclear inflammatory cells.

Note : All biopsy specimen will be stored for 15 (fifteen)days, block and slides for 5(five) years only from the time of receipt at the laboratory. No request ,for any of the above ,will be entertained after the due date.

Reference

- Rosai and Ackerman's Surgical Pathology.
- Modern Surgical Pathology.

Gulshan Yadav, MD
Consultant Pathologist