

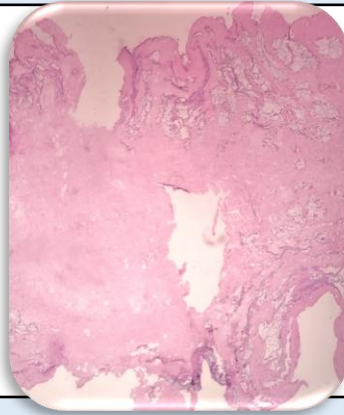
| | | | | | |
|---------------------|------------------|--------------------|--------------------|--------------------------|------------|
| Patient Name | Mrs. PREETI DEVI | Client Name | Accurate Path (C), | Specimen Received | 19/06/2018 |
| Age/Sex | 19/M | | Agra | Specimen Type | Tissue |
| Patient ID | 011806130009 | Client Code | MolQ1671CM | Collection Date | 19/06/2018 |
| Specimen ID | MOLQ/B-556-18 | Ref. Doctor | | Report Date | 21/06/2018 |

SURGICAL PATHOLOGY REPORT

RECTAL POLYP.

DIAGNOSIS

BENIGN RECTAL POLYP.



SPECIMEN

Rectal Polyp.

GROSS

Received 1.0 x 0.5 cm greyish white tissue piece.
E/A

Microscopy

1. Section examined shows fibrocollagenous tissue with mucoid material and autolytic changes in the glands.
2. No granuloma seen.
3. No malignant cells seen.

Note : All biopsy specimen will be stored for 15 (fifteen) days, block and slides for 5 (five) years only from the time of receipt at the laboratory. No request, for any of the above, will be entertained after the due date.

Reference

- i) Rosai and Ackerman's Surgical Pathology.
- ii) Modern Surgical Pathology.

Gulshan Yadav, MD
Consultant Pathologist