

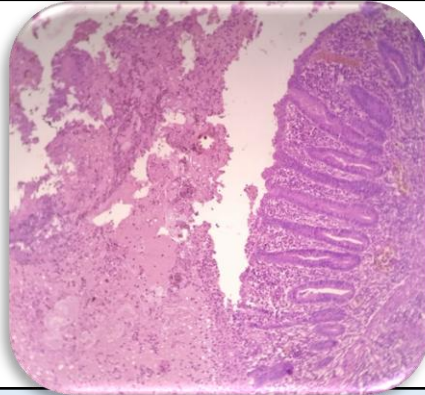
|                     |                   |                    |                          |                          |            |
|---------------------|-------------------|--------------------|--------------------------|--------------------------|------------|
| <b>Patient Name</b> | Mr. ASIF/T.WANGAM | <b>Client Name</b> | A-One Collection Centre, | <b>Specimen Received</b> | 14/06/2018 |
| <b>Age/Sex</b>      | 24/M              |                    | Jammu & Kashmir          | <b>Specimen Type</b>     | Tissue     |
| <b>Patient ID</b>   | 041806140037      | <b>Client Code</b> | MolQ1492CM               | <b>Collection Date</b>   | 14/06/2018 |
| <b>Specimen ID</b>  | MOLQ/B-566/18     | <b>Ref. Doctor</b> | SUPREME LAB              | <b>Report Date</b>       | 18/06/2018 |

## SURGICAL PATHOLOGY REPORT

### APPENDIX.

#### DIAGNOSIS

**ACUTE APPENDICITIS.**



#### SPECIMEN

Appendix.

#### GROSS

Received one greyish white tissue piece. Size: 9.0 x 1.5 cms.

#### Microscopy

1. Section examined shows lymphoid follicles with ulcerative mucosa.
2. Deeper tissue shows inflammatory cells.

**Note :** All biopsy specimen will be stored for 15 (fifteen) days, block and slides for 5 (five) years only from the time of receipt at the laboratory. No request ,for any of the above ,will be entertained after the due date.

#### Reference

- i) Rosai and Ackerman's Surgical Pathology.
- ii) Modern Surgical Pathology.

**Gulshan Yadav, MD  
Consultant Pathologist**