

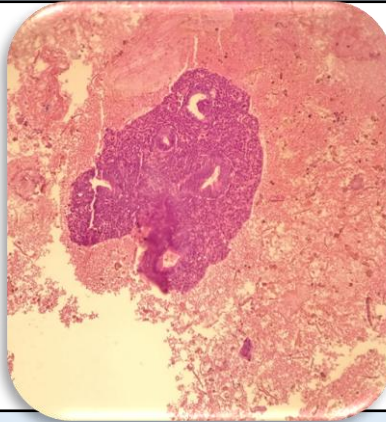
<b>Patient Name</b>	Mrs. UMAN	<b>Client Name</b>	Prakash Hospital, Gurgaon.	<b>Specimen Received</b>	16/06/2018
<b>Age/Sex</b>	25/F	<b>Client Code</b>	MOLQ1098CM	<b>Specimen Type</b>	Tissue
<b>Patient ID</b>	011806160152	<b>Ref. Doctor</b>		<b>Collection Date</b>	16/06/2018
<b>Specimen ID</b>	MOLQ/B-573/18			<b>Report Date</b>	20/06/2018

## SURGICAL PATHOLOGY REPORT

### ENDOMETRIUM.

#### DIAGNOSIS

**PROLIFERATIVE PHASE.**



#### **SPECIMEN**

Endometrium.

#### **GROSS**

Received multiple greyish white tissue piece.

#### **Microscopy**

1. Section examined shows small endometrial glands lined by cuboidal lining epithelium and small round to oval nucleus.
2. Stroma shows mononuclear inflammatory cells.
3. Section also shows fibrin and RBCs.
4. No granuloma seen.
5. No malignant cells seen.

**Note :** All biopsy specimen will be stored for 15 (fifteen) days, block and slides for 5 (five) years only from the time of receipt at the laboratory. No request ,for any of the above ,will be entertained after the due date.

#### **Reference**

- i) Rosai and Ackerman's Surgical Pathology.
- ii) Modern Surgical Pathology.

**Gulshan Yadav, MD**  
**Consultant Pathologist**