

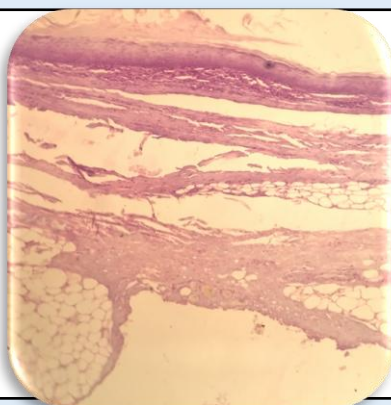
<b>Patient Name</b>	Mr. PHOOL CHAND	<b>Client Name</b>	Civil Hospital-P Gurgaon.	<b>Specimen Received</b>	15/06/2018
<b>Age/Sex</b>	37/M	<b>Client Code</b>	MolQ1681P	<b>Specimen Type</b>	Tissue
<b>Patient ID</b>	011806150233	<b>Ref. Doctor</b>		<b>Collection Date</b>	15/06/2018
<b>Specimen ID</b>	MOLQ/B-570/18			<b>Report Date</b>	19/06/2018

## SURGICAL PATHOLOGY REPORT

### SEBACEOUS CYST.

#### DIAGNOSIS

**SEBACEOUS CYST.**



#### SPECIMEN

Sebaceous Cyst.

#### GROSS

Received 2.2 x 1.9 cms greyish white tissue piece. Cut section shows white necrotic material.

#### Microscopy

1. Section examined shows squamous epithelial lining with keratin flakes, fibrocollagenous tissue and blood vessels.
2. No granuloma seen.
3. No malignant cells seen.

**Note :** All biopsy specimen will be stored for 15 (fifteen)days, block and slides for 5(five) years only from the time of receipt at the laboratory. No request ,for any of the above ,will be entertained after the due date.

#### Reference

- i) Rosai and Ackerman's Surgical Pathology.
- ii) Modern Surgical Pathology.

**Gulshan Yadav, MD**  
Consultant Pathologist