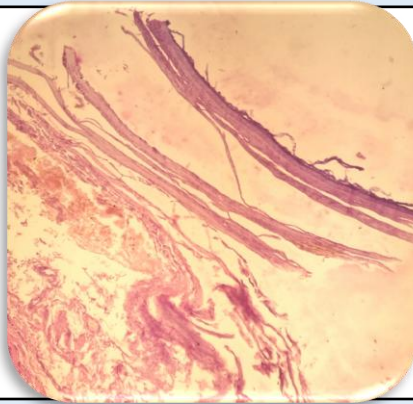


<b>Patient Name</b>	Mr. Mukesh	<b>Client Name</b>	Gobind Hospital, Gurgoan.	<b>Specimen Received</b>	13/06/2018
<b>Age/Sex</b>	46/M	<b>Client Code</b>	MolQ1232CM	<b>Specimen Type</b>	Tissue
<b>Patient ID</b>	011806130221	<b>Ref. Doctor</b>		<b>Collection Date</b>	13/06/2018
<b>Specimen ID</b>	MOLQ/B-560/18			<b>Report Date</b>	19/06/2018

**SURGICAL PATHOLOGY REPORT**  
**SEBACEOUS CYST (SCROTUM WALL)**

**DIAGNOSIS**

**SEBACEOUS CYST.**



**SPECIMEN**

Sebaceous Cyst (Scrotum Wall).

**GROSS**

Received 2.0 x 2.6 cms greyish white tissue piece with attached skin. Cut section shows cheesy material.

**Microscopy**

- Section examined shows squamous epithelial lining with keratin flakes, fibrocollagenous tissue and blood vessels.

**Note :** All biopsy specimen will be stored for 15 (fifteen)days, block and slides for 5(five) years only from the time of receipt at the laboratory. No request ,for any of the above ,will be entertained after the due date.

**Reference**

- Rosai and Ackerman's Surgical Pathology.
- Modern Surgical Pathology.

**Gulshan Yadav, MD**  
**Consultant Pathologist**