

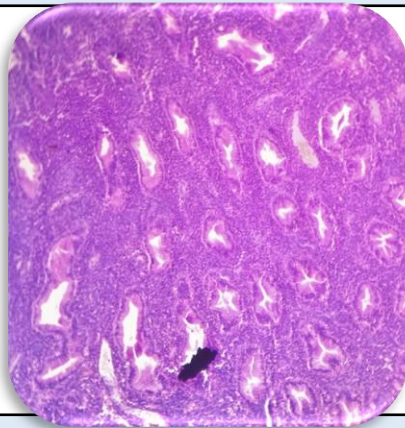
<b>Patient Name</b>	Mrs. SIMRAN	<b>Client Name</b>	Health Medicos,	<b>Specimen Received</b>	12/06/2018
<b>Age/Sex</b>	21/F		Rohtak	<b>Specimen Type</b>	Tissue
<b>Patient ID</b>	011806120294	<b>Client Code</b>	MolQ1394CM	<b>Collection Date</b>	12/06/2018
<b>Specimen ID</b>	MOLQ/B-554/18	<b>Ref. Doctor</b>		<b>Report Date</b>	18/06/2018

## SURGICAL PATHOLOGY REPORT

### ENDOMETRIUM.

#### DIAGNOSIS

**DISORDERED PROLIFERATIVE PHASE.**



#### **SPECIMEN**

Endometrium.

#### **GROSS**

Received multiple greyish white tissue piece.

#### **Microscopy**

- Section examined shows small endometrial glands with tortuous glands having round to oval nucleus. Stroma shows mononuclear inflammatory cells.

**Note :** All biopsy specimen will be stored for 15 (fifteen) days, block and slides for 5 (five) years only from the time of receipt at the laboratory. No request, for any of the above, will be entertained after the due date.

#### **Reference**

- Rosai and Ackerman's Surgical Pathology.
- Modern Surgical Pathology.

**Gulshan Yadav, MD**  
Consultant Pathologist