

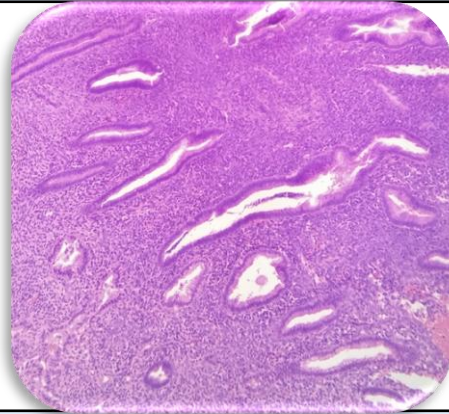
Patient Name	Mrs. SWAPNIL	Client Name	Path Star Diagnostic	Specimen Received	12/06/2018
Age/Sex	41/F		Delhi	Specimen Type	Tissue
Patient ID	011806120293	Client Code	MOLQ1098CM	Collection Date	12/06/2018
Specimen ID	MOLQ/B-542/18	Ref. Doctor		Report Date	18/06/2018

SURGICAL PATHOLOGY REPORT

ENDOMETRIUM.

DIAGNOSIS

PROLIFERATIVE PHASE.



SPECIMEN

Endometrium.

GROSS

Received multiple greyish white tissue piece.

Microscopy

1. Section examined shows autolytic tissue changes with small endometrial glands with round to oval nucleus. Stroma shows mononuclear inflammatory cells.
2. No granuloma seen.
3. No malignant cells seen.

Note : All biopsy specimen will be stored for 15 (fifteen) days, block and slides for 5 (five) years only from the time of receipt at the laboratory. No request, for any of the above, will be entertained after the due date.

Reference

- i) Rosai and Ackerman's Surgical Pathology.
- ii) Modern Surgical Pathology.

**Gulshan Yadav, MD
Consultant Pathologist**