

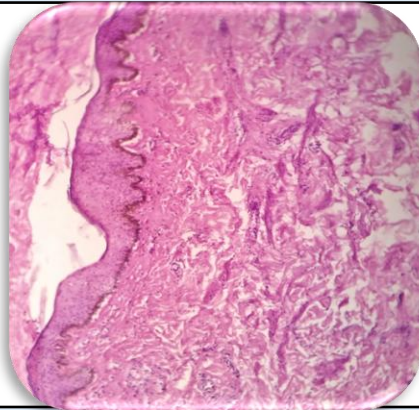
Patient Name	Mr. SATISH	Client Name	Civil Hospital-P, Gurgoan.	Specimen Received	12/06/2018
Age/Sex	28/F	Client Code	MolQ1681P	Specimen Type	Tissue
Patient ID	011806120282	Ref. Doctor		Collection Date	12/06/2018
Specimen ID	MOLQ/B-551/18			Report Date	18/06/2018

SURGICAL PATHOLOGY REPORT

CYST.

DIAGNOSIS

BENIGN CYSTIC LESION.



SPECIMEN

Cyst.

GROSS

Received autolyzed 3.0 x 1.8 cm greyish white tissue piece. Cut section shows necrotic material.

Microscopy

1. Section examined shows squamous epithelial lining with round to oval nucleus with keratin flakes. Dermis shows fibrocollagenous tissue with blood vessels.

Note : All biopsy specimen will be stored for 15 (fifteen) days, block and slides for 5 (five) years only from the time of receipt at the laboratory. No request, for any of the above, will be entertained after the due date.

Reference

- i) Shafers 7th Edition,
- ii) Rosai and Ackerman's Surgical Pathology.
- ii) Modern Surgical Pathology.

Gulshan Yadav, MD
Consultant Pathologist