

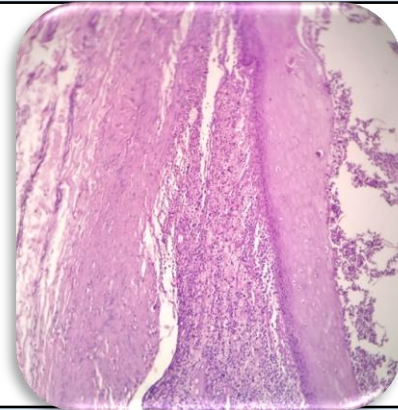
<b>Patient Name</b>	Mr. SURAJPAL	<b>Client Name</b>	Civil Hospital-P, Gurgoan.	<b>Specimen Received</b>	12/06/2018
<b>Age/Sex</b>	60/F	<b>Client Code</b>	MolQ1681P	<b>Specimen Type</b>	Tissue
<b>Patient ID</b>	011806120234	<b>Ref. Doctor</b>		<b>Collection Date</b>	12/06/2018
<b>Specimen ID</b>	MOLQ/B-550/18			<b>Report Date</b>	18/06/2018

## SURGICAL PATHOLOGY REPORT

### SEBACEOUS CYST.

#### DIAGNOSIS

**INFECTED SEBACEOUS CYST WITH FOREIGN BODY TYPE OF GRNAULOMA.**



#### **SPECIMEN**

Sebaceous Cyst.

#### **GROSS**

Received 7.0 x 3.2 cm greyish white tissue piece. Cut section shows necrotic material.

#### **Microscopy**

- Section examined shows squamous epithelial lining, fibrocollagenous tissue with inflammatory cells (polymorphs, lymphocytes, plasma cells and multinucleated giant cells) with necrosis.

**Note :** All biopsy specimen will be stored for 15 (fifteen)days, block and slides for 5(five) years only from the time of receipt at the laboratory. No request ,for any of the above ,will be entertained after the due date.

#### **Reference**

- Shafers 7<sup>th</sup> Edition,
- Rosai and Ackerman's Surgical Pathology.
- Modern Surgical Pathology.

**Gulshan Yadav, MD**  
Consultant Pathologist