

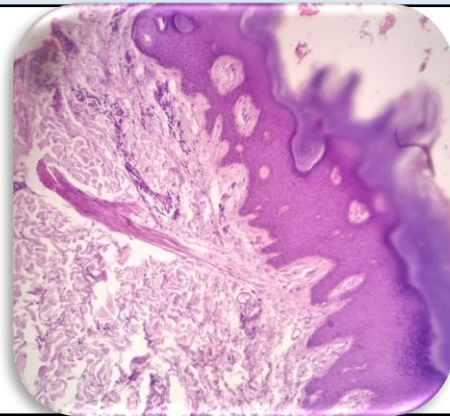
Patient Name	Mr. Sahil	Client Name	Civil Hospital-P	Specimen Received	12/06/2018
Age/Sex	20/M	Client Code	MolQ1681P	Specimen Type	Tissue
Patient ID	011806120098	Ref. Doctor		Collection Date	12/06/2018
Specimen ID	MOLQ/B-546/18			Report Date	14/06/2018

SURGICAL PATHOLOGY REPORT

WART LEFT LEG.

DIAGNOSIS

WART.



SPECIMEN

Wart Left Leg.

GROSS

Received 3.0 x 2.5 cms greyish white tissue piece.

Microscopy

1. Section examined shows Squamous epithelial lining with marked hyperkeratosis and parakeratosis.
2. No granuloma seen.
3. No malignant cells seen.

Note : All biopsy specimen will be stored for 15 (fifteen)days, block and slides for 5(five) years only from the time of receipt at the laboratory. No request ,for any of the above ,will be entertained after the due date.

Reference

- i) Rosai and Ackerman's Surgical Pathology.
- ii) Modern Surgical Pathology.

Gulshan Yadav, MD
Consultant Pathologist