

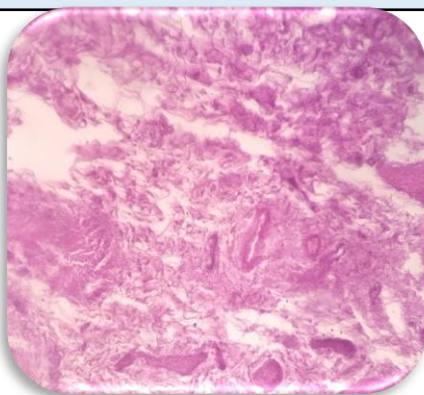
<b>Patient Name</b>	Mrs. Sharda	<b>Client Name</b>	Civil Hospital-P	<b>Specimen Received</b>	12/06/2018
<b>Age/Sex</b>	32/F	<b>Client Code</b>	MolQ1681P	<b>Specimen Type</b>	Tissue
<b>Patient ID</b>	011806120024	<b>Ref. Doctor</b>	DR SAURABH	<b>Collection Date</b>	12/06/2018
<b>Specimen ID</b>	MOLQ/B-544/18			<b>Report Date</b>	14/06/2018

## SURGICAL PATHOLOGY REPORT

### GALL BLADDER.

#### DIAGNOSIS

**CHOLECYSTITIS AND CHOLELITHIASIS.**



#### SPECIMEN

Gall Bladder.

#### GROSS

Received 6.5 x 3.2 cms long gall bladder. Cut section shows stones.

#### Microscopy

- Section examined shows autolyzed ulcerative lining epithelium with mononuclear inflammatory infiltrate.

**Note :** All biopsy specimen will be stored for 15 (fifteen)days, block and slides for 5(five) years only from the time of receipt at the laboratory. No request ,for any of the above ,will be entertained after the due date.

#### Reference

- Rosai and Ackerman's Surgical Pathology.
- Modern Surgical Pathology.

**Gulshan Yadav, MD**  
Consultant Pathologist