

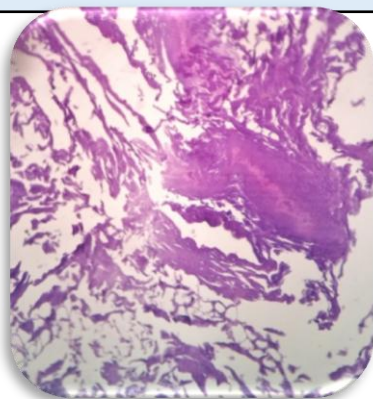
Patient Name	Mrs. Usha	Client Name	Vedic Hospital, Gurgaon.	Specimen Received	11/06/2018
Age/Sex	45/F	Client Code	MolQ1492CM	Specimen Type	Tissue
Patient ID	011806110016	Ref. Doctor		Collection Date	11/06/2018
Specimen ID	MOLQ/B-535/18			Report Date	13/06/2018

SURGICAL PATHOLOGY REPORT

GALL BLADDER.

DIAGNOSIS

CHRONIC CHOLECYSTITIS AND CHOLELITHIASIS.



SPECIMEN

Gall Bladder.

GROSS

Received 6.1 x 3.2 cms long gall bladder. Cut section shows tiny stone.

Microscopy

- Section examined shows autolyzed ulcerated lining epithelium with mononuclear inflammatory cells.

Note : All biopsy specimen will be stored for 15 (fifteen)days, block and slides for 5(five) years only from the time of receipt at the laboratory. No request ,for any of the above ,will be entertained after the due date.

Reference

- Rosai and Ackerman's Surgical Pathology.
- Modern Surgical Pathology.

Gulshan Yadav, MD
Consultant Pathologist