

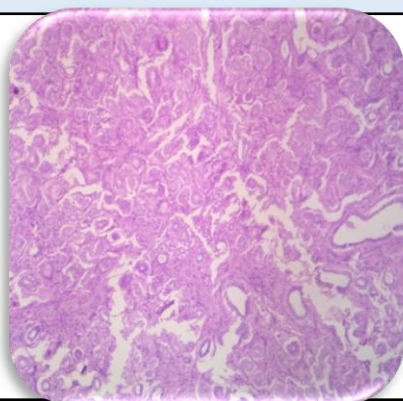
Patient Name	Ms. Manish	Client Name	Civil Hospital, Gurgaon	Specimen Received	01/06/2018
Age/Sex	15/F	Client Code	MolQ1681P	Specimen Type	Tissue
Patient ID	011806010223	Ref. Doctor	Dr. Balwinder Singhji	Collection Date	01/06/2018
Specimen ID	MOLQ/B-498/18			Report Date	08/03/2018

SURGICAL PATHOLOGY REPORT

FIBROADENOMA BREAST.

DIAGNOSIS

BENIGN BREAST LESION.



SPECIMEN

Fibroadenoma Breast.

GROSS

Received 3.0 x 2.9 cms greyish white tissue piece.

Microscopy

- Section examined shows large number of ducts lined by cuboidal epithelium with round vasicular nucleus surrounded by fibrocollagenous tissue and myoepithelial cells with mild anisonucleosis.

Note : All biopsy specimen will be stored for 15 (fifteen)days, block and slides for 5(five) years only from the time of receipt at the laboratory. No request ,for any of the above ,will be entertained after the due date.

Reference

- Rosai and Ackerman's Surgical Pathology.
- Modern Surgical Pathology.

Gulshan Yadav, MD
Consultant Pathologist