

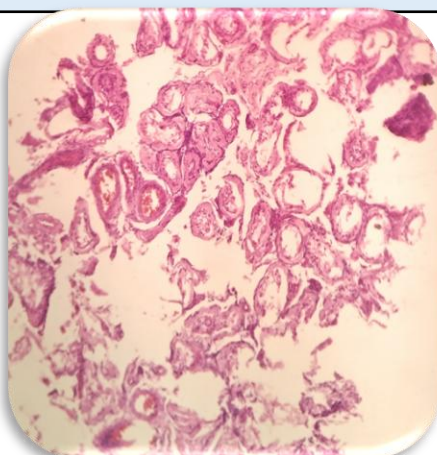
<b>Patient</b>	Mr. JAFRUDDIN	<b>Client Name</b>	Goyal Ultrasound & Diagnostic Center	<b>Specimen Received</b>	07/05/2018
<b>Age/Sex</b>	38/M	<b>Client Code</b>	MolQ1664P	<b>Specimen Type</b>	Tissue
<b>Patient ID</b>	011805060072	<b>Ref. Doctor</b>		<b>Collection Date</b>	07/05/2018
<b>Specimen ID</b>	MOLQ/B-368/18			<b>Report Date</b>	14/05/2018

## SURGICAL PATHOLOGY REPORT

### LEFT TESTIS.

#### DIAGNOSIS

**ATROPHIC TESTIS.**



#### SPECIMEN

Left Testis

#### GROSS

1) Received 4.0 x 3.0 cm long testis.

#### Microscopy

1. Section examined shows seminiferous tubules immature sperm together cells and sporting cell with thick basement.
2. No granuloma and no malignant cell seen.

**Note :** All biopsy specimen will be stored for 15 (fifteen) days, block and slides for 5 (five) years only from the time of receipt at the laboratory. No request ,for any of the above ,will be entertained after the due date.

#### Reference

- i) Rosai and Ackerman's Surgical Pathology.
- ii) Modern Surgical Pathology.

**Gulshan Yadav, MD**  
Consultant Pathologist