

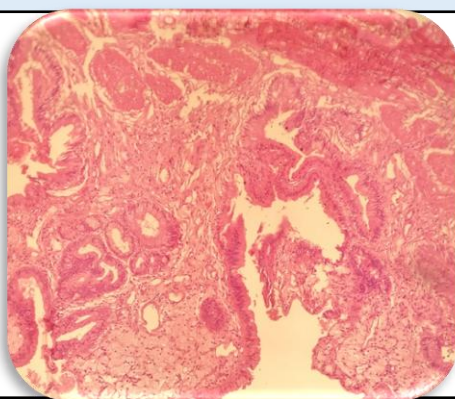
Patient Name	Mrs. MAHIMA	Client Name	Accurate Path (C),	Specimen Received	06/05/2018
Age/Sex	28/F		Agra	Specimen Type	Tissue
Patient ID	011805060008	Client Code	MolQ1671CM	Collection Date	06/05/2018
Specimen ID	MOLQ/B-367/18	Ref. Doctor	DR VINEET VERMA	Report Date	12/05/2018

SURGICAL PATHOLOGY REPORT

GALL BLADDER.

DIAGNOSIS

CHOLECYSTITIS WITH CHOLELITHIASIS.



SPECIMEN

Gall Bladder.

GROSS

1) Received 6.2 x 1.8 cm long gall bladder with stone.

Microscopy

1. Section examined shows ulcerative mucosa and rokitansky aschoff sinus with fibrocollagenous tissue.
2. No granuloma seen.
3. No malignant cells seen.

Note : All biopsy specimen will be stored for 15 (fifteen) days, block and slides for 5 (five) years only from the time of receipt at the laboratory. No request ,for any of the above ,will be entertained after the due date.

Reference

- i) Rosai and Ackerman's Surgical Pathology.
- ii) Modern Surgical Pathology.

Gulshan Yadav, MD
Consultant Pathologist