

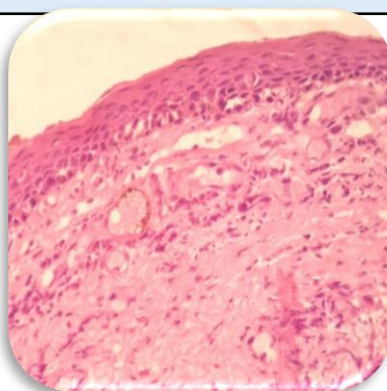
Patient Name	Master Anuradh	Client Name	Agarwal Pathology,	Specimen Received	05/05/2018
Age/Sex	07/M		Agra	Specimen Type	Tissue
Patient ID	011805050001	Client Code	MolQ1420CM	Collection Date	05/05/2018
Specimen ID	MOLQ/B-361/18	Ref. Doctor		Report Date	11/05/2018

SURGICAL PATHOLOGY REPORT

CONJUCTIVAL CYST.

DIAGNOSIS

BENIGN INFLAMMATORY CYSTIC LESION.



SPECIMEN

Conjunctival Cyst.

GROSS

1) Received multiple greyish white tissue pieces.


Microscopy

1. Section examined shows squamous lining epithelium with small round nucleus.
2. Deeper tissue show fibrocollagenous tissue blood vessels with large number of inflammatory cell (polymorph, lymphocytes and plasma cells).
3. No granuloma seen.
4. No maliganant cells seen

Note : All biopsy specimen will be stored for 15 (fifteen) days, block and slides for 5 (five) years only from the time of receipt at the laboratory. No request ,for any of the above ,will be entertained after the due date.

Reference

- i) Rosai and Ackerman's Surgical Pathology.
- ii) Modern Surgical Pathology.



Gulshan Yadav, MD
Consultant Pathologist