

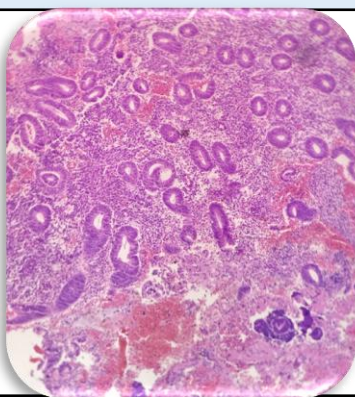
<b>Patient Name</b>	Mrs. MONIKA	<b>Client Name</b>	BIRJANAND PATH LAB	<b>Specimen Received</b>	05/05/2018
<b>Age/Sex</b>	26/F	<b>Client Code</b>	MOLQ1133CM	<b>Specimen Type</b>	Tissue
<b>Patient ID</b>	011805050185	<b>Ref. Doctor</b>		<b>Collection Date</b>	05/05/2018
<b>Specimen ID</b>	MOLQ/B-364/18			<b>Report Date</b>	08/05/2018

## SURGICAL PATHOLOGY REPORT

### ENDOMETRIUM TISSUE.

#### DIAGNOSIS

**SIMPLE HYPERPLASIA WITHOUT ATYPIA.**



#### SPECIMEN

Endometrium tissue.

#### GROSS

1) Received multiple greyish white tissue pieces.

#### Microscopy

- 1) Section examined shows small endometrial gland with cystically dilated gland , having round to oval nucleus.
- 2) Stroma shows mononuclear inflammatory cells.

**Note :** All biopsy specimen will be stored for 15 (fifteen) days, block and slides for 5 (five) years only from the time of receipt at the laboratory. No request ,for any of the above ,will be entertained after the due date.

#### Reference

- i) Rosai and Ackerman's Surgical Pathology.
- ii) Modern Surgical Pathology.

**Gulshan Yadav, MD**  
Consultant Pathologist