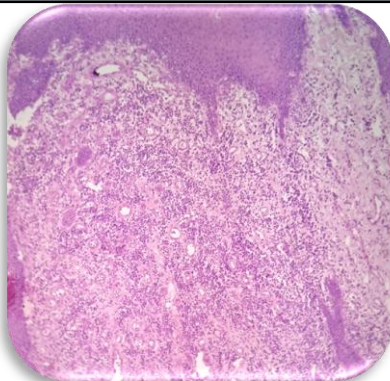


Patient Name	Mrs. OMBARI	Client Name	EKTAA HOSPITAL, GURGAON.	Specimen Received	02/05/2018
Age/Sex	65 /F	Client Code	MolQ1324P	Specimen Type	Tissue
Patient ID	011805020163	Ref. Doctor		Collection Date	02/05/2018
Specimen ID	MOLQ/B-346/18			Report Date	04/05/2018

SURGICAL PATHOLOGY REPORT
PIRIFOAM FOSSA.

DIAGNOSIS

MODERATELY DIFFERENTIATED SQUAMOUS CELL CARCINOMA.



SPECIMEN

Pirifoam fossa

GROSS

- 1) Received multiple greyish white tissue pieces.

Microscopy

- 1) Section examined shows Squamous epithelial cell in sheets and in groups.
- 2) Cells shows large atypical vesicular nucleus and nucleoli.
- 3) Cell also shows anisonucleosis, surrounded by fibrocollagenous tissue and inflammatory cells.
- 4) Section shows mitotic figures.

Note : All biopsy specimen will be stored for 15 (fifteen) days, block and slides for 5 (five) years only from the time of receipt at the laboratory. No request ,for any of the above ,will be entertained after the due date.

Reference

- i) Rosai and Ackerman's Surgical Pathology.
- ii) Modern Surgical Pathology.



Gulshan Yadav, MD
Consultant Pathologist