

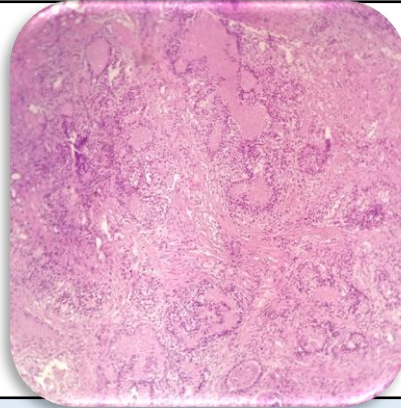
Patient Name	Mr. PRAKASH CHAND	Client Name	LIFE AID WELLNESS CENTRE	Specimen Received	01/05/2018
Age/Sex	58 /M			Specimen Type	Tissue
Patient ID	011805010183	Client Code	MolQ1476CM	Collection Date	01/05/2018
Specimen ID	MOLQ/B-344/18	Ref. Doctor		Report Date	04/05/2018

SURGICAL PATHOLOGY REPORT

T.U.R.P.

DIAGNOSIS

BENIGN PROSTATIC HYPERPLASIA .



SPECIMEN

T.U.R.P.

GROSS

1) Received multiple greyish white tissue pieces.

Microscopy

1) Section examined shows bilayered prostatic glands with columnar lining epithelium and with small round to oval nucleus surrounded by large number of fibrocollagenous tissue and mononuclear inflammatory cell.

Note : All biopsy specimen will be stored for 15 (fifteen) days, block and slides for 5 (five) years only from the time of receipt at the laboratory. No request ,for any of the above ,will be entertained after the due date.

Reference

- Rosai and Ackerman's Surgical Pathology.
- Modern Surgical Pathology.

Report generated at MolQ Laboratory, Gurgaon


MD
Consultant Pathologist