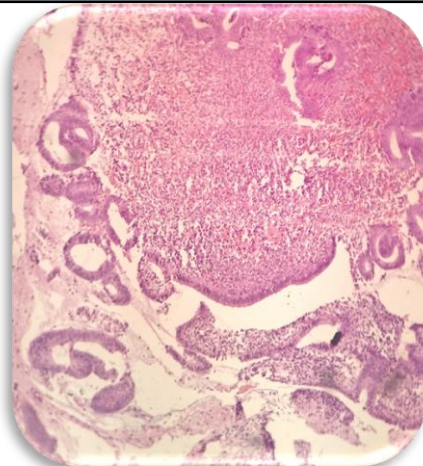


| | | | | | |
|---------------------|------------------|--------------------|------------------------|--------------------------|------------|
| Patient Name | Mrs. ANITA YADAV | Client Name | LIFEID WELLNESS CENTER | Specimen Received | 27/04/2018 |
| Age/Sex | 31 /F | | | Specimen Type | Tissue |
| Patient ID | 011804270224 | Client Code | MolQ1476CM | Collection Date | 27/04/2018 |
| Specimen ID | MOLQ/B-337/18 | Ref. Doctor | | Report Date | 01/05/2018 |

SURGICAL PATHOLOGY REPORT **ENDOMETRIUM POLYP.**

DIAGNOSIS

ENDOMETRIAL POLYP.



SPECIMEN

Endometrium polyp.

GROSS

1) Received multiple greyish white tissue pieces.

Microscopy

- 1) Section examined shows lining epithelium having small round nucleus with endometrial glands.
- 2) Stroma shows mononuclear inflammatory cell and RBC.

Note : All biopsy specimen will be stored for 15 (fifteen) days, block and slides for 5 (five) years only from the time of receipt at the laboratory. No request ,for any of the above ,will be entertained after the due date.

Reference

- i) Rosai and Ackerman's Surgical Pathology.
- ii) Modern Surgical Pathology.



Gulshan Yadav, MD
Consultant Pathologist