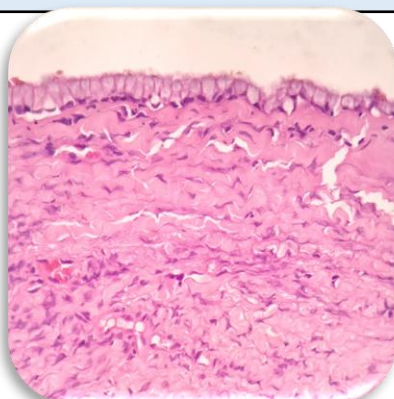


<b>Patient Name</b>	Mrs. NIRMAL	<b>Client Name</b>	CYGNUS SUPERSPECIALITY	<b>Specimen Received</b>	27/04/2018
<b>Age/Sex</b>	25/F		HOSPITAL, REWARI	<b>Specimen Type</b>	Tissue
<b>Patient ID</b>	011804270188	<b>Client Code</b>	MolQ1687CM	<b>Collection Date</b>	27/04/2018
<b>Specimen ID</b>	MOLQ/B-334/18	<b>Ref. Doctor</b>		<b>Report Date</b>	30/04/2018

## SURGICAL PATHOLOGY REPORT OVARIAN CYST.

### DIAGNOSIS

**CYST ADENOMA.**



### SPECIMEN

Ovarian cyst .

### GROSS

- 1) Received two greyish white tissue pieces.
- 2) Already cut open uniloculation.

### Microscopy

- 1) Section examined shows lining epithelium with small round to oval nucleus with stromal cells and blood vessels.
- 2) No malignant and no granuloma seen.

**Note :** All biopsy specimen will be stored for 15 (fifteen) days, block and slides for 5 (five) years only from the time of receipt at the laboratory. No request ,for any of the above ,will be entertained after the due date.

### Reference

- i) Rosai and Ackerman's Surgical Pathology.
- ii) Modern Surgical Pathology.



**Gulshan Yadav, MD**  
Consultant Pathologist