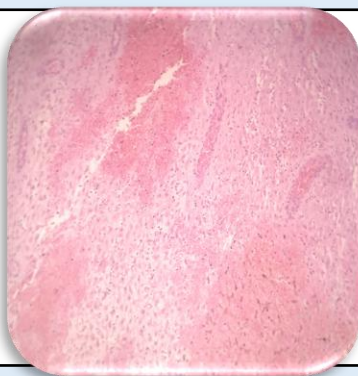


<b>Patient Name</b>	Mrs. SONI	<b>Client Name</b>	R.S. DIAGNOSTIC	<b>Specimen Received</b>	24/04/2018
<b>Age/Sex</b>	45 /F		KAPASHERA	<b>Specimen Type</b>	Tissue
<b>Patient ID</b>	011804240010	<b>Client Code</b>	MOLQ1062CM	<b>Collection Date</b>	24/04/2018
<b>Specimen ID</b>	MOLQ/B-328/18	<b>Ref. Doctor</b>		<b>Report Date</b>	28/04/2018

**SURGICAL PATHOLOGY REPORT**  
**ENDOMETRIUM TISSUE.**

**DIAGNOSIS**

**DECIDUAL CAST.**



**SPECIMEN**

Endometrium tissue.

**GROSS**

- 1) Received 5.0 x 1.9 cm greyish white tissue pieces with blood clot.

**Microscopy**

- 1) Section examined shows decidual cells having round to oval nucleus with large number of blood vessels and few endometrial gland.

**Note :** All biopsy specimen will be stored for 15 (fifteen) days, block and slides for 5 (five) years only from the time of receipt at the laboratory. No request ,for any of the above ,will be entertained after the due date.

**Reference**

- i) Rosai and Ackerman's Surgical Pathology.
- ii) Modern Surgical Pathology.

**Gulshan Yadav, MD**  
**Consultant Pathologist**