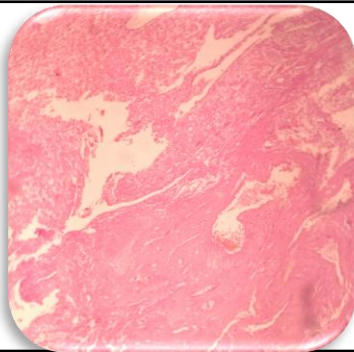


<b>Patient Name</b>	Mrs. SADHNA DEVI	<b>Client Name</b>	ACCURATE PATH,	<b>Specimen Received</b>	24/04/2018
<b>Age/Sex</b>	40 /F		AGRA	<b>Specimen Type</b>	Tissue
<b>Patient ID</b>	011804230260	<b>Client Code</b>	MolQ1671CM	<b>Collection Date</b>	24/04/2018
<b>Specimen ID</b>	MOLQ/B-326/18	<b>Ref. Doctor</b>		<b>Report Date</b>	28/04/2018

## SURGICAL PATHOLOGY REPORT UTERUS WITH CERVIX.

### DIAGNOSIS

DECIDUAL CAST.



### SPECIMEN

Uterus with cervix.

### GROSS

- 1) Received 10.0 x 5.3 cm long uterus with cervix.
- 2) Already cut open thick endometrium 5mm.

### Microscopy

- 1) Section examined shows few endometrial gland with decidual cell.
- 2) Myometrium shows muscle bundle. Cervix shows mononuclear inflammatory cell.
- 3) Decidual cells with degenerated trophoblastic cells, inflammatory cell blood vessels.

**Note :** All biopsy specimen will be stored for 15 (fifteen) days, block and slides for 5 (five) years only from the time of receipt at the laboratory. No request ,for any of the above ,will be entertained after the due date.

### Reference

- i) Rosai and Ackerman's Surgical Pathology.
- ii) Modern Surgical Pathology.

Gulshan Yadav, MD  
Consultant Pathologist