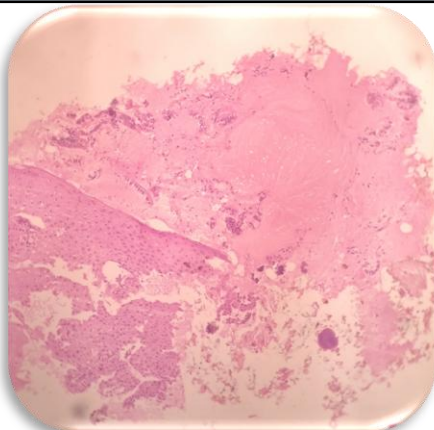


<b>Patient Name</b>	Mrs. LALI DEVI	<b>Client Name</b>	CGYNUS SUPERSPECIALITY	<b>Specimen Received</b>	24/04/2018
<b>Age/Sex</b>	55/F		HOSPITAL, REWARI	<b>Specimen Type</b>	Tissue
<b>Patient ID</b>	011804240322	<b>Client Code</b>	MoIQ1687CM	<b>Collection Date</b>	24/04/2018
<b>Specimen ID</b>	MOLQ/B-331/18	<b>Ref. Doctor</b>		<b>Report Date</b>	27/04/2018

## **SURGICAL PATHOLOGY REPORT** **ENDOMETRIUM TISSUE.**

### **DIAGNOSIS**

**KINDLY CORRELATE CLINICALLY.**



### **SPECIMEN**

Endometrium tissue

### **GROSS**

1) Received multiple greyish white tissue pieces.

### **Microscopy**

- 1) Paucicellular scanty broken endometrial gland having cuboidal lining epithelium with few stromal cell and RBC.
- 2) Section also shows few broken Squamous epithelial cell (cervix).
- 3) No malignant and no granuloma seen.

**Note :** All biopsy specimen will be stored for 15 (fifteen) days, block and slides for 5 (five) years only from the time of receipt at the laboratory. No request ,for any of the above ,will be entertained after the due date.

### **Reference**

- i) Rosai and Ackerman's Surgical Pathology.
- ii) Modern Surgical Pathology.

A handwritten signature in black ink, appearing to read 'Gulshan', written over a light blue rectangular background.

**Gulshan Yadav, MD**  
**Consultant Pathologist**