

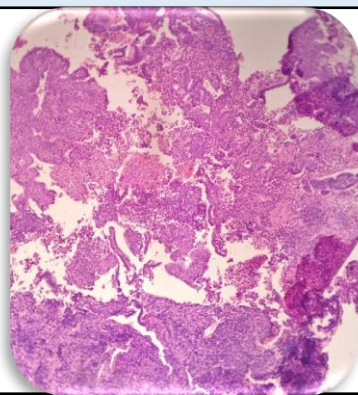
<b>Patient Name</b>	Mrs. MADHU GOYAL	<b>Client Name</b>	LIFE AID WELLNESS CENTRE	<b>Specimen Received</b>	23/04/2018
<b>Age/Sex</b>	46/F			<b>Specimen Type</b>	Tissue
<b>Patient ID</b>	011804230010	<b>Client Code</b>	MolQ1476CM	<b>Collection Date</b>	23/04/2018
<b>Specimen ID</b>	MOLQ/B-322/18	<b>Ref. Doctor</b>		<b>Report Date</b>	25/04/2018

## **SURGICAL PATHOLOGY REPORT**

### **ENDOMETRIUM TISSUE.**

#### **DIAGNOSIS**

**DISORDERED PROLIFERATIVE PHASE WITH SIMPLE HYPERPLASIA WITHOUT ATYPIA.**



#### **SPECIMEN**

Endometrium tissue.

#### **GROSS**

1) Received multiple greyish white tissue pieces.

#### **Microscopy**

- 1) Section examined shows small and tortuous endometrial gland with cuboidal lining epithelium round to oval nucleus.
- 2) Few cystically dilated gland present.
- 3) Stroma shows mononuclear inflammatory cell.
- 4) No malignant and no granuloma seen.

**Note :** All biopsy specimen will be stored for 15 (fifteen) days, block and slides for 5 (five) years only from the time of receipt at the laboratory. No request ,for any of the above ,will be entertained after the due date.

#### **Reference**

- i) Rosai and Ackerman's Surgical Pathology.
- ii) Modern Surgical Pathology.

A handwritten signature in black ink, appearing to read 'Gulshan', written over a light blue rectangular background.

**Gulshan Yadav, MD  
Consultant Pathologist**

*Report generated at MolQ Laboratory, Gurgaon*