

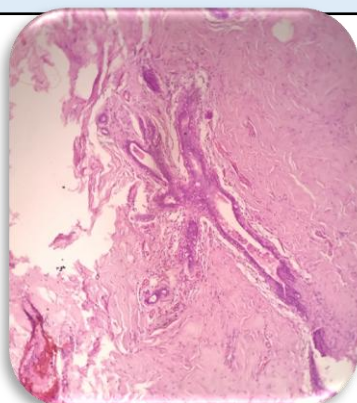
| | | | | | |
|---------------------|---------------------|--------------------|------------------|--------------------------|------------|
| Patient Name | MISS. SHIVANI SINGH | Client Name | GOBIND HOSPITAL, | Specimen Received | 22/04/2018 |
| Age/Sex | 22/F | | Gurgaon. | Specimen Type | Tissue |
| Patient ID | 011804220002 | Client Code | MolQ1232CM | Collection Date | 22/04/2018 |
| Specimen ID | MOLQ/B-321/18 | Ref. Doctor | | Report Date | 25/04/2018 |

SURGICAL PATHOLOGY REPORT

FIBROADENOMA RIGHT BREAST.

DIAGNOSIS

BENIGN BREAST LESION.



SPECIMEN

Fibroadenoma Right Breast

GROSS

1) Received 4.0 x 2.0 cm long tissue piece.

Microscopy

- 1) Section examined shows large number of duct with cuboidal lining epithelium and small round nucleus with large number of fibrocollagenous tissue.
- 2) No malignant and no granuloma seen.

Note : All biopsy specimen will be stored for 15 (fifteen) days, block and slides for 5 (five) years only from the time of receipt at the laboratory. No request ,for any of the above ,will be entertained after the due date.

Reference

- i) Rosai and Ackerman's Surgical Pathology.
- ii) Modern Surgical Pathology.

Gulshan Yadav, MD
Consultant Pathologist

Report generated at MolQ Laboratory, Gurgaon