

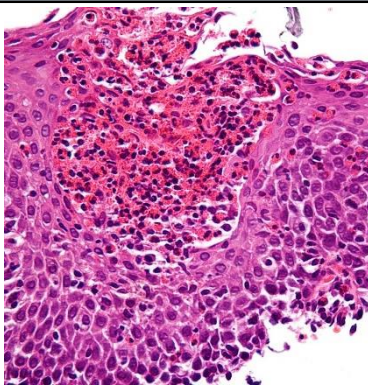
Patient Name	Mrs. CHANDA	Client Name	Vedic Hospital	Specimen Received	04/04/2018
Age/Sex	24/F	Client Code	MOLQ1492CM	Specimen Type	Tissue
Patient ID	011804040202	Ref. Doctor		Collection Date	04/04/2018
Specimen ID	MOLQ/B-250/18			Report Date	11/04/2018

SURGICAL PATHOLOGY REPORT

Cyst.

DIAGNOSIS

PARASITIC INFESTATION. (CYSTICERCOSIS)



SPECIMEN

Cyst.

GROSS

1) Received 1x1cm greyish white tissue piece.

Microscopy

- 1) Section examined shows muscle bundle, fibrocollagenous tissue, blood vessels and inflammatory cells. (Plasma cells, lymphocytes, histocytes few polymorphs)
- 2) Section also shows membranes.
- 3) No granuloma and no malignant cell seen.

Note : All biopsy specimen will be stored for 15 (fifteen)days, block and slides for 5(five) years only from the time of receipt at the laboratory. No request ,for any of the above ,will be entertained after the due date.

Reference

- i) Rosai and Ackerman's Surgical Pathology.
- ii) Modern Surgical Pathology.

Gulshan Yadav, MD
Consultant Pathologist