

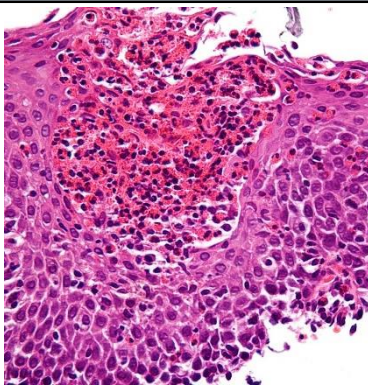
<b>Patient Name</b>	Mrs. CHANDA	<b>Client Name</b>	Vedic Hospital	<b>Specimen Received</b>	04/04/2018
<b>Age/Sex</b>	24/F	<b>Client Code</b>	MOLQ1492CM	<b>Specimen Type</b>	Tissue
<b>Patient ID</b>	011804040180	<b>Ref. Doctor</b>		<b>Collection Date</b>	04/04/2018
<b>Specimen ID</b>	MOLQ/B-249/18			<b>Report Date</b>	11/04/2018

## SURGICAL PATHOLOGY REPORT

**Cyst.**

### DIAGNOSIS

**PARASITIC INFESTATION. (CYSTICERCOSIS)**



### SPECIMEN

Cyst.

### GROSS

1) Received 1x2cm greyish white tissue piece.

### Microscopy

- 1) Section examined shows muscle bundle, fibrocollagenous tissue, blood vessels and inflammatory cells. (Plasma cells, lymphocytes, histocytes, few polymorphs).
- 2) Section also show multilayered cyst wall.
- 3) No granuloma and no malignant cell seen.

**Note :** All biopsy specimen will be stored for 15 (fifteen)days, block and slides for 5(five) years only from the time of receipt at the laboratory. No request ,for any of the above ,will be entertained after the due date.

### Reference

- i) Rosai and Ackerman's Surgical Pathology.
- ii) Modern Surgical Pathology.

**Gulshan Yadav, MD**  
**Consultant Pathologist**