

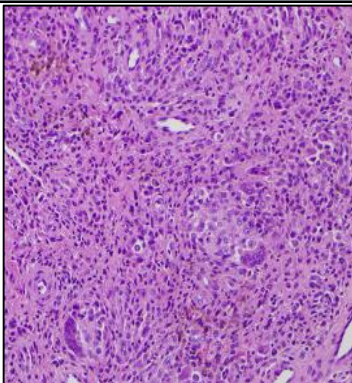
Patient Name	Mrs. JASMINE	Client Name	Kailash Nursing Home	Specimen Received	02/04/2018
Age/Sex	24/F	Client Code	MOLQ1171P	Specimen Type	Tissue
Patient ID	011804030024	Ref. Doctor		Collection Date	02/04/2018
Specimen ID	MOLQ/B-247/18			Report Date	08/04/2018

SURGICAL PATHOLOGY REPORT

Endometrium biopsy.

DIAGNOSIS

PROLIFERATIVE PHASE.



SPECIMEN

Endometrium biopsy.

GROSS

1) Received multiple greyish white tissue pieces.

Microscopy

- 1) Section examined shows small endometrium glands having cuboidal lining epithelium with small nucleus.
- 2) Stroma shows mononuclear inflammatory infiltrate.
- 3) No granuloma and no malignant cell seen in sample receive.

Note : All biopsy specimen will be stored for 15 (fifteen) days, block and slides for 5 (five) years only from the time of receipt at the laboratory. No request, for any of the above, will be entertained after the due date.

Reference

- i) Rosai and Ackerman's Surgical Pathology.
- ii) Modern Surgical Pathology.

Gulshan Yadav, MD
Consultant Pathologist