

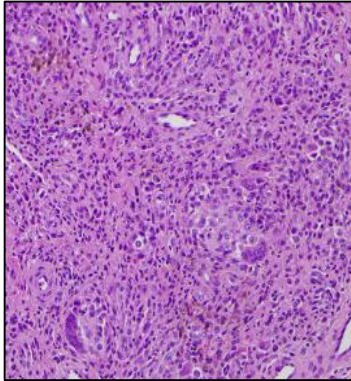
<b>Patient Name</b>	Mrs. VARSHA W/O DEEPAK	<b>Client Name</b>	Health Medicos, Rohtak	<b>Specimen Received</b>	02/04/2018
<b>Age/Sex</b>	23/F	<b>Client Code</b>	MolQ1394CM	<b>Specimen Type</b>	Tissue
<b>Patient ID</b>	011804020266	<b>Ref. Doctor</b>		<b>Collection Date</b>	02/04/2018
<b>Specimen ID</b>	MOLQ/B-246/18			<b>Report Date</b>	08/04/2018

## SURGICAL PATHOLOGY REPORT

Endometrium.

### DIAGNOSIS

**PROLIFERATIVE PHASE.**



### SPECIMEN

Endometrium.

### GROSS

- 1) Received multiple greyish white tissue pieces.

### Microscopy

- 1) Section examined shows small endometrium glands heaving cuboidal lining epithelium with small nucleus.
- 2) Stroma shows mononuclear inflammatory infiltrate.
- 3) No granuloma and no malignant cell seen in sample receive.

**Note :** All biopsy specimen will be stored for 15 (fifteen)days, block and slides for 5(five) years only from the time of receipt at the laboratory. No request ,for any of the above ,will be entertained after the due date.

### Reference

- i) Rosai and Ackerman's Surgical Pathology.
- ii) Modern Surgical Pathology.

**Gulshan Yadav, MD**  
Consultant Pathologist