

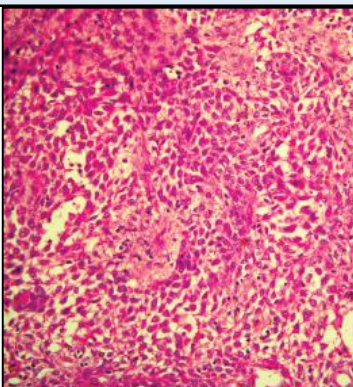
<b>Patient Name</b>	Mr. JAMSHED	<b>Client Name</b>	Vashist Path Lab	<b>Specimen Received</b>	27/03/2018
<b>Age/Sex</b>	32/F	<b>Client Code</b>	MolQ1688P	<b>Specimen Type</b>	Tissue
<b>Patient ID</b>	011803270186	<b>Ref. Doctor</b>		<b>Collection Date</b>	27/03/2018
<b>Specimen ID</b>	MOLQ/B-229/18			<b>Report Date</b>	03/04/2018

## SURGICAL PATHOLOGY REPORT

### Oral cavity.

#### DIAGNOSIS

**BENIGN MESENCHYMAL LESION WITH MILD INFLAMMATION.**



#### SPECIMEN

Oral cavity.

#### GROSS

1) Received multiple greyish white tissue pieces.

#### Microscopy

- 1) Section examined shows Squamous epithelial small epithelial with small round nucleus with large number of blood vessels with fibrocollagenous tissue.
- 2) Areas of bony fragment.
- 3) Section also shows inflammatory cells (Polymorph, lymphocyte, plasma cells).
- 4) No malignant and no granuloma seen in sample received.

**Note :** All biopsy specimen will be stored for 15 (fifteen)days, block and slides for 5(five) years only from the time of receipt at the laboratory. No request ,for any of the above ,will be entertained after the due date.

#### Reference

- i) Rosai and Ackerman's Surgical Pathology.
- ii) Modern Surgical Pathology.

**Gulshan Yadav, MD**  
Consultant Pathologist