

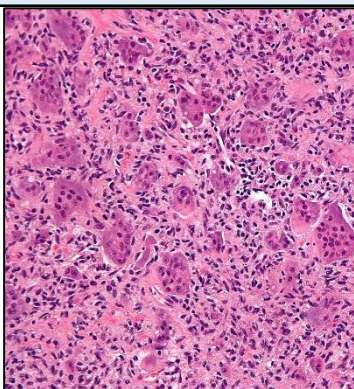
<b>Patient Name</b>	Mrs. SHUMITRA DEVI	<b>Client Name</b>	Brijanand Path Lab	<b>Specimen Received</b>	27/03/2018
<b>Age/Sex</b>	60/F	<b>Client Code</b>	MolQ1133CM	<b>Specimen Type</b>	Tissue
<b>Patient ID</b>	011803270073	<b>Ref. Doctor</b>		<b>Collection Date</b>	27/03/2018
<b>Specimen ID</b>	MOLQ/B-227/18			<b>Report Date</b>	03/04/2018

## SURGICAL PATHOLOGY REPORT

Endometrium biopsy.

### DIAGNOSIS

**KINDLY CORRELATE CLINICALLY AND RADIOLOGICALLY.**



### SPECIMEN

Endometrium biopsy.

### GROSS

1) Received multiple greyish white tissue pieces.

### Microscopy

- 1) Section examined shows predominantly mononuclear stromal cell, blood clot.
- 2) No endometrial gland seen in sample received.

**Note :** All biopsy specimen will be stored for 15 (fifteen)days, block and slides for 5(five) years only from the time of receipt at the laboratory. No request ,for any of the above ,will be entertained after the due date.

### Reference

- i) Rosai and Ackerman's Surgical Pathology.
- ii) Modern Surgical Pathology.

**Gulshan Yadav, MD**  
Consultant Pathologist