

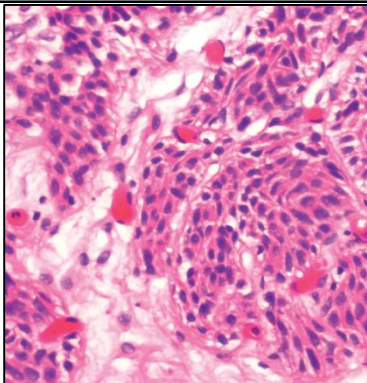
Patient Name	Mrs. PHOOLWATI	Client Name	Gobind Hospital	Specimen Received	22/03/2018
Age/Sex	33/F	Client Code	MolQ1232CM	Specimen Type	Tissue
Patient ID	011803220111	Ref. Doctor		Collection Date	22/03/2018
Specimen ID	MOLQ/B-213/18			Report Date	28/03/2018

SURGICAL PATHOLOGY REPORT

Fallopian tubes.

DIAGNOSIS

BOTH FALLOPIAN TUBE CONFIRM AND UNREMARKABLE.



SPECIMEN

Fallopian tubes.

GROSS

- 1) Received 1x1cm greyish white tissue piece.
- 2) Received 1.5x0.5cm greyish white tissue piece.

Microscopy

- 1) Section examined shows tubal lining epithelium with fibrocollagenous tissue.

Note : All biopsy specimen will be stored for 15 (fifteen)days, block and slides for 5(five) years only from the time of receipt at the laboratory. No request ,for any of the above ,will be entertained after the due date.

Reference

- i) Rosai and Ackerman's Surgical Pathology.
- ii) Modern Surgical Pathology.

Gulshan Yadav, MD
Consultant Pathologist