

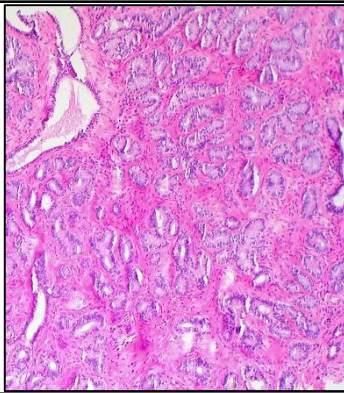
Patient Name	Mr. JVBER	Client Name	Global Diagnostic Center,	Specimen Received	14/03/2018
Age/Sex	34/M	Tauru		Specimen Type	Tissue
Patient ID	011801290166	Client Code	MolQ1703P	Collection Date	14/03/2018
Specimen ID	MOLQ/B-190/18	Ref. Doctor		Report Date	17/03/2018

SURGICAL PATHOLOGY REPORT

Benign breast lesion , Breast.

DIAGNOSIS

BENIGN BREAST LESION.



SPECIMEN

Breast.

GROSS

1. Received 5x3cm long greyish white tissue piece.

Microscopy

- 1) Section examined shows mature adipose cells bits of squamous lining epithelium, fibrocollagenous tissue with ducts having cuboidal lining epithelium having small round nucleus with stromal cells.

Note : All biopsy specimen will be stored for 15 (fifteen)days, block and slides for 5(five) years only from the time of receipt at the laboratory. No request ,for any of the above ,will be entertained after the due date.

Reference

- i) Rosai and Ackerman's Surgical Pathology.
- ii) Modern Surgical Pathology.

Dr. Gulshan Yadav, MD
Consultant Pathologist