

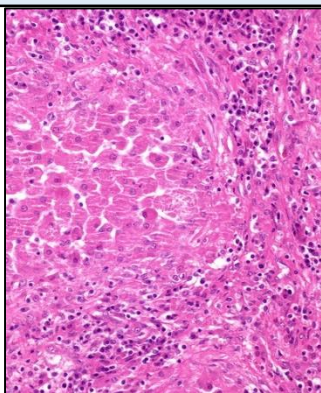
<b>Patient Name</b>	Mrs. SUMAN DEVI	<b>Client Name</b>	Accurate Path (C), Agra	<b>Specimen Received</b>	19/02/2018
<b>Age/Sex</b>	40/F	<b>Client Code</b>	MolQ1671CM	<b>Specimen Type</b>	Tissue
<b>Patient ID</b>	011802190209	<b>Ref. Doctor</b>		<b>Collection Date</b>	19/02/2018
<b>Specimen ID</b>	MOLQ/B-145/18			<b>Report Date</b>	12/03/2018

## SURGICAL PATHOLOGY REPORT

### Endometrium biopsy.

#### DIAGNOSIS

**DISORDERED PROLIFERATIVE PHASE.**



#### SPECIMEN

Endometrium biopsy.

#### GROSS

1) Received autolyzed multiple tissue pieces.

#### Microscopy

- 1) Autolyzed section examined shows small and tortuous endometrial gland having cuboidal lining epithelium with round to oval nucleus.
- 2) Stroma show mononuclear inflammatory cell.

**Note :** All biopsy specimen will be stored for 15 (fifteen)days, block and slides for 5(five) years only from the time of receipt at the laboratory. No request ,for any of the above ,will be entertained after the due date.

#### Reference

- i) Rosai and Ackerman's Surgical Pathology.
- ii) Modern Surgical Pathology.

**Dr. Gulshan Yadav, MD**  
Consultant Pathologist