

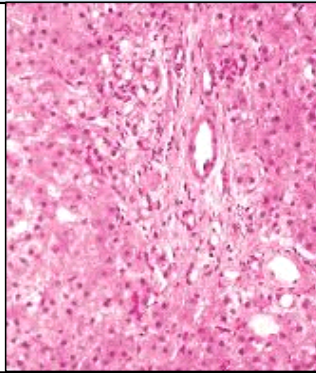
<b>Patient Name</b>	Mrs. SUBANI	<b>Client Name</b>	Goyal Ultrasound &	<b>Specimen Received</b>	20/02/2018
<b>Age/Sex</b>	65/F		Diagnostic Center	<b>Specimen Type</b>	Tissue
<b>Patient ID</b>	011802200017	<b>Client Code</b>	MolQ1664P	<b>Collection Date</b>	20/02/2018
<b>Specimen ID</b>	MOLQ/B-146/18	<b>Ref. Doctor</b>		<b>Report Date</b>	24/02/2018

## SURGICAL PATHOLOGY REPORT

### Gall bladder.

#### DIAGNOSIS

**CHOLECYSTITIS WITH CHOLELITHIASIS.**



#### SPECIMEN

Gall bladder.

#### GROSS

- 1) Received 6.1x1.8cm long gall bladder.
- 2) Cut section shows tiny stones.

#### Microscopy

- 1) Section examined shows ulcerative mucosa and rokitansky aschoff sinus with fibrocollagenous tissue.

**Note :** All biopsy specimen will be stored for 15 (fifteen) days, block and slides for 5 (five) years only from the time of receipt at the laboratory. No request, for any of the above, will be entertained after the due date.

#### Reference

- i) Rosai and Ackerman's Surgical Pathology.
- ii) Modern Surgical Pathology.

A handwritten signature in black ink, appearing to read 'Gulshan'.

**Dr. Gulshan Yadav, MD**  
**Consultant Pathologist**