

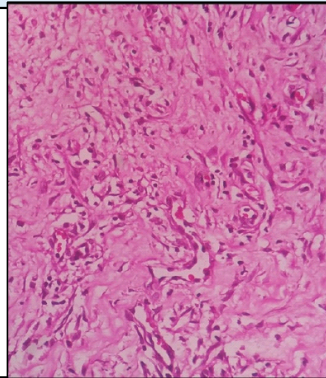
<b>Patient Name</b>	Mrs. KAMLESH	<b>Client Name</b>	Lifeaid Wellness Centre	<b>Specimen Received</b>	18/02/2018
<b>Age/Sex</b>	36/F			<b>Specimen Type</b>	Tissue
<b>Patient ID</b>	011802180041	<b>Client Code</b>	MolQ1476CM	<b>Collection Date</b>	18/02/2018
<b>Specimen ID</b>	MOLQ/B-140/18	<b>Ref. Doctor</b>		<b>Report Date</b>	24/02/2018

## SURGICAL PATHOLOGY REPORT

### Endometrium biopsy.

#### DIAGNOSIS

**KINDLY CORRELATE CLINICALLY.**



#### SPECIMEN

Endometrium biopsy.

#### GROSS

- 1) Received tiny greyish white tissue pieces.

#### Microscopy

- 1) Paucicellular Section examined shows only few broken endometrial glands with large number of mononuclear stromal cells.
- 2) No granuloma and no malignant cell seen.

**Note :** All biopsy specimen will be stored for 15 (fifteen) days, block and slides for 5 (five) years only from the time of receipt at the laboratory. No request, for any of the above, will be entertained after the due date.

#### Reference

- i) Rosai and Ackerman's Surgical Pathology.
- ii) Modern Surgical Pathology.

**Dr. Gulshan Yadav, MD**  
Consultant Pathologist