

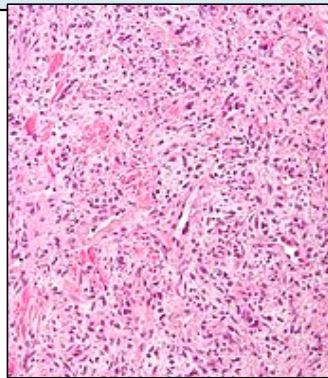
Patient Name	Mrs. KAMLA DEVI	Client Name	Noble Diagnostic, Rohtak	Specimen Received	17/02/2018
Age/Sex	65/F	Client Code	MolQ1690CM	Specimen Type	Tissue
Patient ID	011802170238	Ref. Doctor		Collection Date	17/02/2018
Specimen ID	MOLQ/B-136/18			Report Date	23/02/2018

SURGICAL PATHOLOGY REPORT

Mesentery swelling.

DIAGNOSIS

BENIGN MESENCHYMAL LESION.



SPECIMEN

Mesentery swelling.

GROSS

1) Received 1x1.5cm greyish white tissue piece (In).

Microscopy

- 1) Section examined shows fibrocollagenous tissue with large number of mature adipose cells.
- 2) No malignant and no granuloma seen.

Note : All biopsy specimen will be stored for 15 (fifteen) days, block and slides for 5 (five) years only from the time of receipt at the laboratory. No request, for any of the above, will be entertained after the due date.

Reference

- i) Rosai and Ackerman's Surgical Pathology.
- ii) Modern Surgical Pathology.

Dr. Gulshan Yadav, MD
Consultant Pathologist