

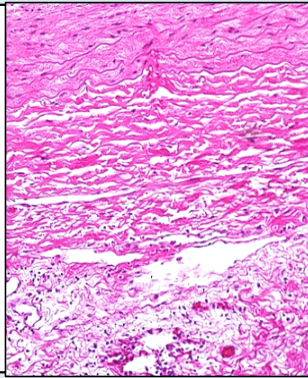
<b>Patient Name</b>	Mr. MUKESH	<b>Client Name</b>	Ubuntu Health Solutions	<b>Specimen Received</b>	16/02/2018
<b>Age/Sex</b>	51/M		Pvt. Ltd	<b>Specimen Type</b>	Tissue
<b>Patient ID</b>	011802160244	<b>Client Code</b>	MolQ1517CM	<b>Collection Date</b>	16/02/2018
<b>Specimen ID</b>	MOLQ/B-131/18	<b>Ref. Doctor</b>		<b>Report Date</b>	22/02/2018

## SURGICAL PATHOLOGY REPORT

### Right lung.

#### DIAGNOSIS

**ENPHYSEMATOTUS LUNG.**



#### SPECIMEN

Right lung.

#### GROSS

1) Received 12.5x1.2cm wezed shaped tissue piece.

#### Microscopy

- 1) Section examined shows large alvioli with small fenestral in the walls ,breakdown and merging of fibrovascular trabeculae.
- 2) No malignant cell seen.

**Note :** All biopsy specimen will be stored for 15 (fifteen)days, block and slides for 5(five) years only from the time of receipt at the laboratory. No request ,for any of the above ,will be entertained after the due date.

#### Reference

- i) Rosai and Ackerman's Surgical Pathology.
- ii) Modern Surgical Pathology.

**Dr. Gulshan Yadav, MD**  
Consultant Pathologist