

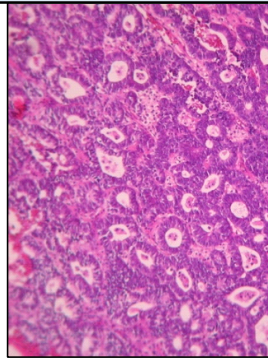
Patient Name	Mrs. MAMTA	Client Name	Star Hospital	Specimen Received	12/02/2018
Age/Sex	42/F			Specimen Type	Tissue
Patient ID	011802120218	Client Code	MolQ1255CM	Collection Date	12/02/2018
Specimen ID	MOLQ/B-123/18	Ref. Doctor		Report Date	21/02/2018

SURGICAL PATHOLOGY REPORT

Endometrium.

DIAGNOSIS

SIMPLE HYPERPLASIA WITHOUT ATYPIA.



SPECIMEN:

Endometrium.

GROSS:

- 1) Received multiple greyish white tissue pieces.

Microscopy

- 1) Section examined shows small endometrium glands cuboidal lining epithelium with small round nucleus with few cystically dilated glands.
- 2) Stroma shows mononuclear inflammatory cells.

Note : All biopsy specimen will be stored for 15 (fifteen) days, block and slides for 5 (five) years only from the time of receipt at the laboratory. No request, for any of the above, will be entertained after the due date.

Reference

- i) Rosai and Ackerman's Surgical Pathology.
- ii) Modern Surgical Pathology.

A handwritten signature in black ink, appearing to read 'Gulshan', written over a white rectangular background.

Gulshan Yadav, MD
Consultant Pathologist