

<b>Patient Name</b>	Mr. JAGDISH	<b>Client Name</b>	North Delhi Diagnostic	<b>Specimen Received</b>	14/02/2018
<b>Age/Sex</b>	52/M			<b>Specimen Type</b>	Tissue
<b>Patient ID</b>	011802140103	<b>Client Code</b>	MolQ1219P	<b>Collection Date</b>	14/02/2018
<b>Specimen ID</b>	MOLQ/B-126/18	<b>Ref. Doctor</b>		<b>Report Date</b>	20/02/2018

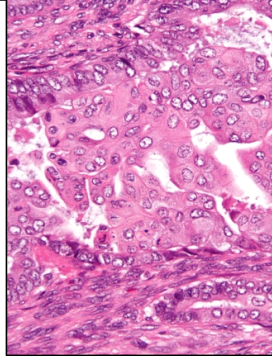
## SURGICAL PATHOLOGY REPORT

### Lateral malleolus ulcer.

#### DIAGNOSIS

**BENIGN MESENCHYMAL LESION WITH NON SPECIFIC INFLAMMATION .**

**ADVICE:- Deeper Biopsy.**



#### SPECIMEN:

Lateral malleolus ulcer.

#### GROSS:

1) Received 1x1cm greyish white tissue piece .

#### Microscopy

- 1) Section examined shows fibrocollagenous tissue with large number of blood vessels and inflammatory cells.
- 2) No granuloma seen.

**Note :** All biopsy specimen will be stored for 15 (fifteen)days, block and slides for 5(five) years only from the time of receipt at the laboratory. No request ,for any of the above ,will be entertained after the due date.

#### Reference

- i) Rosai and Ackerman's Surgical Pathology.
- ii) Modern Surgical Pathology.

**Gulshan Yadav, MD  
Consultant Pathologist**