

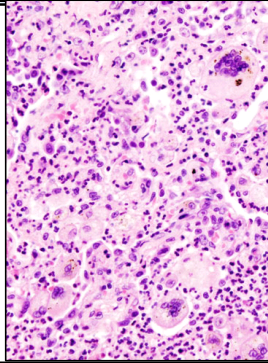
Patient Name	Mr. PARTAP	Client Name	Chauhan Hospital	Specimen Received	10/02/2018
Age/Sex	50/M			Specimen Type	Tissue
Patient ID	011802100174	Client Code	MOLQ1020P	Collection Date	10/02/2018
Specimen ID	MOLQ/B-120/18	Ref. Doctor		Report Date	20/02/2018

SURGICAL PATHOLOGY REPORT

Right Shoulder.

DIAGNOSIS

FOREIGN BODY TYPE OF GRANULOMA.



SPECIMEN:

Right Shoulder.

GROSS:

1) Received 1x1cm greyish white tissue piece.

Microscopy

1) Section examined shows fibrocollagenous tissue, blood vessels with inflammatory cells (lymphocytes and polymorphs) with multinucleated giant cells.

Note : All biopsy specimen will be stored for 15 (fifteen) days, block and slides for 5 (five) years only from the time of receipt at the laboratory. No request, for any of the above, will be entertained after the due date.

Reference

- i) Rosai and Ackerman's Surgical Pathology.
- ii) Modern Surgical Pathology.

Gulshan Yadav, MD
Consultant Pathologist